

16. Cohort Study.” Archives of academic emergency medicine vol. 9,1 e45. 12 Jun. 2021.
17. Gao HN, Lu HZ, Cao B, et al. Clinical findings in 111 cases of influenza A (H7N9) virus infection. *N Engl J Med* 2013; 368: 2277–85.

**Misdiagnosis of Ewing’s sarcoma, A tragedy of a young female initially diagnosed with chronic osteomyelitis and ended with disarticulation (Case report)**

Hassan Mohammed Hassan Elbahri<sup>1</sup>, Mohamed Abdulkarim<sup>2</sup>, Y.N. Gashi<sup>3</sup>, Hozifa Mohammed Ali Abd-Elmaged<sup>4</sup>

**Authors Affiliations and positions:**

Hassan Mohammed Hassan Elbahri<sup>1</sup>

First Author

Associate Professor of Orthopedic oncology.

International University of Africa – Department of Orthopedics.

[hssnbahari0@gmail.com](mailto:hssnbahari0@gmail.com)

Mohamed Abdulkarim<sup>2</sup>

Co-author

Alzaiem Alazhari university – Department of Surgery

[mohd.karim0095@gmail.com](mailto:mohd.karim0095@gmail.com).

Y.N. Gashi<sup>3</sup>

Co-author

Associate professor of orthopedic,

Department of orthopedic University of Khartoum

[y\\_gashi@yahoo.com](mailto:y_gashi@yahoo.com)

Hozifa Mohammed Ali Abd-Elmaged<sup>4</sup>

Co-author

Assistant Professor of Orthopedics

Alzaiem Alazhari university – Department of Orthopedics

[hozifa.m.ali@gmail.com](mailto:hozifa.m.ali@gmail.com)

## **Abstract**

Introduction and importance

Ewing sarcoma is an aggressive malignant primary tumor of bones that usually occurs in adolescents and young adults. It can be difficult to diagnosed and many cases have been reported to be misdiagnosed as another disease entities.

*Case presentation:* A nine years old female presented with a huge swelling involving her left thigh that has eventually turned out to be an Ewing's sarcoma. It was initially managed as a case of chronic

osteomyelitis with drilling of the cortex resulting in seeding of the tumor cells into the whole thigh compartments.

*Clinical findings and investigations:* Patient initially presented with localized swelling in the left thigh and was investigated using plain x-rays revealing non-specific findings followed by an MRI scan which revealed findings suggestive, but not conclusive, of Ewing's sarcoma. Finally, core needle biopsy confirms the diagnosis.

*Interventions and outcome:* Unfortunate but necessary management thereafter with hip disarticulation in addition to chemotherapy was performed freeing the patient from the disease. Biopsy confirming the disease and ensuring clear surgical margins was performed by taking the whole limb for histopathology.

*Conclusions:* Ewing's sarcoma can have features similar to many other conditions, most notably chronic osteomyelitis. Therefore, it can be considered as a differential when suspecting osteomyelitis, especially for patients in their second decade of life.

*Relevance and impact:* Ewing's sarcoma might require a high index of suspicion to be diagnosed since many of its clinical and imaging findings shared with another bone conditions.

**Keywords:** Ewing's sarcoma, disarticulation, Misdiagnosis, osteomyelitis, case report

## **Introduction**

Ewing sarcoma is an aggressive malignant primary tumor of bones or soft tissues that usually occurs in adolescents and young adults (usually in the second decade of life). It is named after James Ewing who was the first one to describe the condition in 1921. Males are three times more likely to get the disease than females and it occurs in Whites more than it does in any other race like Hispanics and Africans. Up to quarter of patients present with metastases at the time they receive their diagnosis and in such case it is usually characterized by resistance to intensive therapy. Treatment of Ewing's sarcoma is dependent on whether the disease is localized or metastatic, but the general theme for treatment is a multimodal approach to the sarcoma including surgical intervention, radiotherapy as well as chemotherapy and a

multidisciplinary team is usually involved in treatment. While this treatment approach is very effective for localized disease, metastatic disease prognosis remains poor (1-3).

### **Patient information**

The patient is a nine years old girl who presented with a huge swelling involving her left thigh for the last 4 months. She has no history of diabetes, hypertension or allergies nor taking any medications. She went through uncomplicated pre, peri and postnatal period, with normal milestone. Developmental history was clear.

Patient was fully vaccinated according to national protocol. No family history of such condition.

### **Clinical findings**

Physical examinations revealed an unwell, cachexic, vitally-stable patient who was pale but not jaundiced or cyanosed. The skin was shiny, tense with multiple dilated veins beside a surgical scar of previous surgery. Whole thigh was tense and swollen from hip to knee (Fig 1). The mass was firm and attached to skin and deep structure. No inguinal lymphadenopathy, with intact distal neurovascular examination. Limited painful range of motion of hip and knee was found.

### **Timeline**

She was quite well till 4 months ago when her mother noticed that she had a limp while walking. At that time there was no swelling. The patient was taken to the hospital where she was treated as having muscular pain with only simple analgesics. One month later she developed a swelling in the left thigh which was associated with mild fever. X-ray, U/S and CBC were done and a diagnosis of chronic osteomyelitis was made. I.V cefuroxime and surgical drainage was attempted. No pus was found, so multiple drill holes was made looking for an intramedullary collection and again nothing drained except an organized hematoma

Patient was deteriorating every day with more pain and more swelling. Parents took their own decision to seek medical advice in the principal hospital. Full clinical, laboratory and radiological workup was

done once the patient received. There was a huge swelling in the left thigh extending from the hip down to the knee

### **Diagnostic assessment and interpretation**

Lab investigation including CBC showed anemia. X rays showed intramedullary lesion at mid shaft femur with onion skin type of periosteal reaction and multiple drill holes on the cortex (Fig 2). MRI showed an enhanced heterogeneous mass at shaft of the femur with soft tissue extension occupying antero- medial and lateral compartment, which raised a high suspicion of malignant tumor. (Fig 3). Core needle biopsy was performed and histology revealed Ewing's sarcoma.

### **Intervention**

The tumor has already been disseminated and extensive involving all the compartments and no chance was left for limb salvage. Neoadjuvant chemotherapy was started and later a left hip disarticulation was performed. The whole limb was then sent to histopathology which confirmed the diagnosis of Ewing's sarcoma, revealed clear surgical resection margins.

### **Follow-up and outcome**

Patient was then referred to receive her chemotherapy sessions. Her wound has recovered well with no infection or dehiscence. She was then followed up for a period of 8 years in the referred clinic and she is now free of disease.

### **Discussion**

Many cases of Ewing's sarcoma can be diagnostically challenging in terms of both the clinical presentation and their radiographic assessment with osteomyelitis being the most notable disease to be confused with it. Other disease entities have also been reported to be confused with Ewing's sarcoma as well. Clinically, constitutional symptoms can occur in both conditions. The presence of an elevated

temperature and bone pain can occur in both Ewing's sarcoma and osteomyelitis along with increased markers of inflammation (4).

Features favoring Ewing's sarcoma over osteomyelitis on radiography include presence of a Codman triangle, a periosteal reaction, a soft tissue mass or merely involvement of the bone metaphysis or adjacent joints. While Ewing's sarcoma is generally characterized on magnetic resonance imaging (MRI) by permeative cortical involvement with soft tissue mass, osteomyelitis has a serpiginous tract involvement. Osteomyelitis occurred more often in African Americans than Ewing's sarcoma did (5).

That is being mentioned, MRI findings can still be inconclusive; thus, a biopsy of the lesion should be performed to confirm or rule out the diagnosis of Ewing's sarcoma. Special attention regarding how to perform the biopsy should be taken and it should be performed cautiously to prevent hematoma formation and, most importantly, infliction of the adjacent joints or neurovascular bundles with tumor cells in case of Ewing's as affected structures must be removed in such case. Therefore, whenever there is a possibility of Ewing's sarcoma, the biopsy should be performed with consultation of an oncological orthopedic department at a sarcoma specialized center as an inappropriate biopsy intake has been reported to result in large areas removal and amputations which could have otherwise been prevented. Marking the site where the biopsy was taken can help with its recognition in surgery after neoadjuvant chemotherapy (4,6).

Confirmation of the disease should be combined with diagnostic modalities to determine whether the disease is localized or has metastasized to other body organs. The most widely acceptable and currently used is the combination of whole-body MRI and chest CT. Combination of PET and MRI scans is getting more popularity (7).

Alexandre Arkader et al. suggested four reasons to miss Ewing's sarcoma diagnosis and establishing another diagnosis which involve an atypical site of the lesion, inadequate biopsy to confirm the disease histologically, absence of malignant features on imaging as well as having a low index of suspicion for the lesion (8).

Histologically, Ewing's sarcoma is characterized by solid growth pattern of small cells that have round nuclei and an abundant glycogen deposition in almost half of cases. Glycogen deposition results in cells

being periodic acid–Schiff (PAS) stain positive cells. Cells with larger nuclei that are PAS negative characterize the atypical variant of Ewing sarcoma (9,10).

After introduction of the multidisciplinary approach to treatment of Ewing sarcoma with the combination of surgery, chemotherapy and radiation, the survival rate has increased to over 50%. Not only that, but even the surgical approach to the tumor has shifted from limb amputation to limb salvage surgery.

## **Conclusion**

In this case we report a case of a 9-year-old girl with Ewing's who was initially thought to have osteomyelitis. As part of osteomyelitis management, an attempt of drilling of the cortex has paved the way for the tumor to extend to all thigh compartments. The limb was beyond salvage at time of presentation. Disarticulation was the final result of the course of the misdiagnosis. Here, the primary surgeon relied on their clinical judgment and had a low level of suspicion.

This case has been reported in line with the SCARE criteria (11).

## **Consent**

An informed consent was obtained from the patient for publication of this case report and accompanying images.

## **Ethical Approval**

No ethical approval was required for publishing this case report.

## **Conflict of Interest**

Authors report no conflict of interest of any sort.

## **Funding**

Authors have not received any funding from any source and this work is completely a voluntary work.

## **Guarantor**

Mohamed Abdulkarim

Hozifa Mohammed Ali Abd-Elmaged

## References

- 1- Gaspar, N. et al. Ewing sarcoma: current management and future approaches through collaboration. *J. Clin. Oncol.* 33, 3036–3046 (2015).
- 2- Durer S, Shaikh H. Ewing Sarcoma. 2022 Jan 25. In: StatPearls [Internet]. Treasure Island (FL): StatPearls Publishing; 2022 Jan–. PMID: 32644609.
- 3- Durer S, Shaikh H. Ewing Sarcoma. [Updated 2022 Jan 25]. In: StatPearls [Internet]. Treasure Island (FL): StatPearls Publishing; 2022 Jan–.
- 4- Zöllner SK, Amatruda JF, Bauer S, Collaud S, de Álava E, DuBois SG, Harges J, Hartmann W, Kovar H, Metzler M, Shulman DS, Streitbürger A, Timmermann B, Toretsky JA, Uhlenbruch Y, Vieth V, Grünewald TGP, Dirksen U. Ewing Sarcoma-Diagnosis, Treatment, Clinical Challenges and Future Perspectives. *J Clin Med.* 2021 Apr 14;10(8):1685. doi: 10.3390/jcm10081685. PMID: 33919988; PMCID: PMC8071040.
- 5- McCarville MB, Chen JY, Coleman JL, Li Y, Li X, Adderson EE, Neel MD, Gold RE, Kaufman RA. Distinguishing Osteomyelitis From Ewing Sarcoma on Radiography and MRI. *AJR Am J Roentgenol.* 2015 Sep;205(3):640-50; quiz 651. doi: 10.2214/AJR.15.14341. PMID: 26295653; PMCID: PMC5744678.
- 6- Jalgaonkar A., Dawson-Bowling S.J., Mohan A.T., Spiegelberg B., Saifuddin A., Pollock R., Skinner J.A., Briggs T.W., Aston W. Identification of the biopsy track in musculoskeletal tumour surgery: A novel technique using India ink. *Bone Joint. J.* 2013;95-B:250–253. doi: 10.1302/0301-620X.95B2.30123
- 7- Daldrup-Link H. How PET/MR Can Add Value for Children with Cancer. *Curr. Radiol. Rep.* 2017;5 doi: 10.1007/s40134-017-0207-y.
- 8- Arkader A, Myung KS, Stanley P, Mascarenhas L. Ewing sarcoma of the tibia mimicking fibrous dysplasia. *J Pediatr Orthop B.* 2013 May;22(3):222-7. doi: 10.1097/BPB.0b013e32834dfe4d. PMID: 22094991.



- 9- Marcilla D., Machado I., Grunewald T.G.P., Llombart-Bosch A., de Alava E. (Immuno)histological Analysis of Ewing Sarcoma. *Methods Mol. Biol.* 2021; 2226:49–64. doi: 10.1007/978-1-0716-1020-6\_5.
- 10- Nascimento A.G., Unii K.K., Pritchard D.J., Cooper K.L., Dahlin D.C. A clinicopathologic study of 20 cases of large-cell (atypical) Ewing's sarcoma of bone. *Am. J. Surg. Pathol.* 1980; 4:29–36. doi: 10.1097/00000478-198004010-00003.
- 11- Agha RA, Franchi T, Sohrabi C, Mathew G, for the SCARE Group. The SCARE 2020 Guideline: Updating Consensus Surgical CAse REport (SCARE) Guidelines, International Journal of Surgery 2020;84:226-230.

**Attached Figures:**

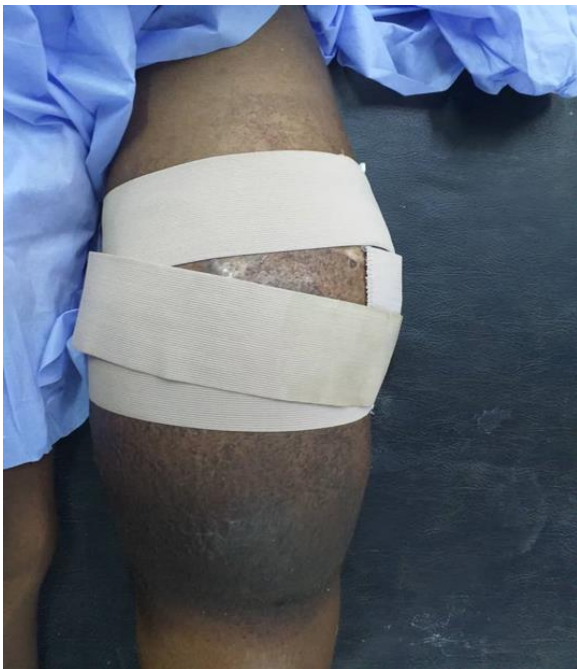

FIGURE 1: REVEALING THAT THE WHOLE THIGH WAS TENSE AND SWOLLEN FROM HIP TO KNEE

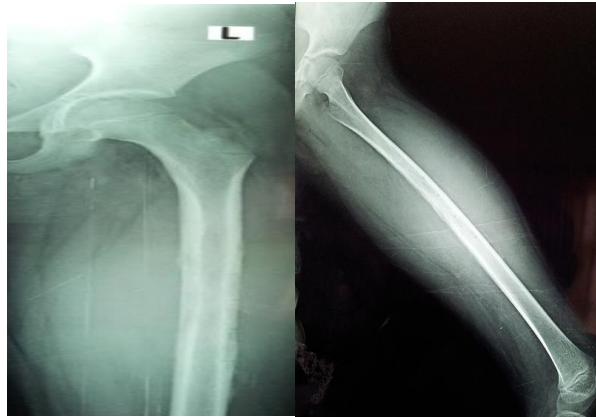


FIGURE 2: X- RAY SHOWS INTRAMEDULLARY LESION AT MID SHAFT FEMUR WITH ONION SKIN TYPE OF PERIOSTEAL REACTION AND MULTIPLE DRILL HOLES ON THE CORTEX.

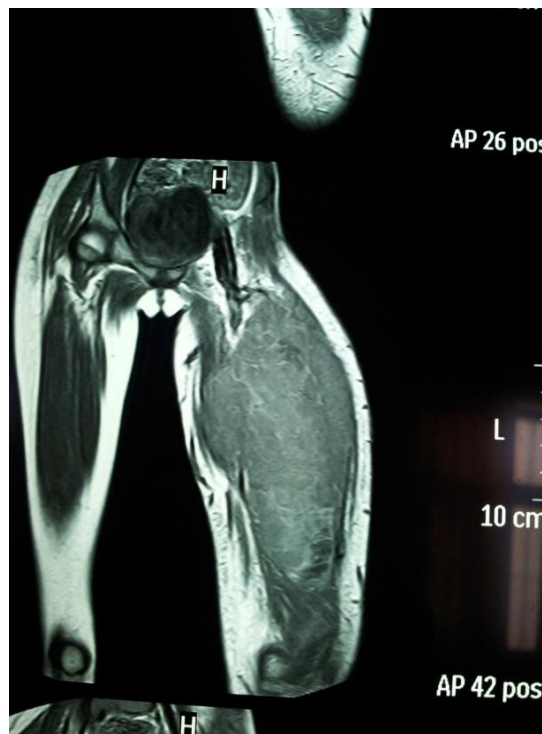


FIGURE 3: MRI SHOWING AN ENHANCED HETEROGENEOUS MASS AT SHAFT OF THE FEMUR WITH SOFT TISSUE EXTENSION OCCUPYING ANTERO- MEDIAL AND LATERAL COMPARTMENT.

### Laser Tonsillectomy in Sudanese patients

Abusufian Hassan Ahamed Elhaj<sup>1,\*</sup>, Nazik Elfadel AAlla<sup>2</sup>and Abd Ellateef Abbass Abd Ellateef <sup>3</sup>

<sup>1</sup>Alnileen University

<sup>2</sup>Khartoum University

<sup>3</sup>Sudan University of science and technology

Correspondence email: [abusufianelhaj@gmail.com](mailto:abusufianelhaj@gmail.com)

### Abstract

**Background:** Laser is an *acronym* of light Amplification by Stimulated Emission of Radiation. Laser light is known to have a high intensity, collimated beam and monochromaticity. Due to these special properties, laser found wide range of applications particularly in medicine including diagnostic and therapeutic. Laser has been used in ENT clinically since late 1970. In the Sudan, Laser is introduced recently in medicine including the ENT, Head and Neck surgery with various operations mainly larynx, oral cavity, neck and tonsillectomy.